



PRESENTING CLINICAL SIGNS

History: Grade III/VI murmur. Asymptomatic.

DATE

12/30/22

ECHOCARDIOGRAPHIC FINDINGS

2D, M-mode, and Doppler study.

PERFORMED BY:

Shari Reffi, CVT

INTERPRETED BY

Keith Blass, DVM,
MS, DACVIM
(Cardiology)

Left atrial size is normal. The mitral valve leaflets are mildly thickened, and a mild jet of eccentric mitral regurgitation is present. Left ventricular dimensions are normal. Left ventricular systolic function is hyperdynamic. The aorta and aortic valve are normal. Right atrial and right ventricular dimensions are normal. The tricuspid valve leaflets are mildly thickened, and a mild to moderate jet of tricuspid regurgitation is present. TR velocity does not suggest the presence of pulmonary hypertension. The pulmonary artery and pulmonic valve appear normal, though trace pulmonic insufficiency is present. No heartworms are visualized. No pericardial effusion or cardiac masses are seen.

PATIENT

Mariposa Romano

LA - 23.9 mm
LVIDd - 23.9 mm
LVIDs - 13.1 mm
FS - 45%
RA - 15.5 mm
LVOT - 1.10 m/s
RVOT - 1.02 m/s
TR - 2.76 m/s

SPECIES

Canine

ASSESSMENT/RECOMMENDATIONS

Degenerative mitral and tricuspid valve disease

BREED

CKCS

This examination demonstrates regurgitation of blood across Mariposa's mitral and tricuspid valves resulting from degenerative valve disease. The hemodynamic effects of each of the regurgitations appear to be mild, as Mariposa does not have secondary dilation of any of her cardiac chambers. As such, Mariposa's valvular diseases appear to be well-compensated, and her current risk for the development of clinical signs secondary to them, such as coughing, exercise intolerance, syncope, labored breathing, and abdominal distension, appears to be low.

SEX

No therapy is recommended at this stage of Mariposa's valvular diseases.

FS

A recheck echocardiogram is recommended in 6 months to monitor for disease progression.

AGE

5 y

WEIGHT

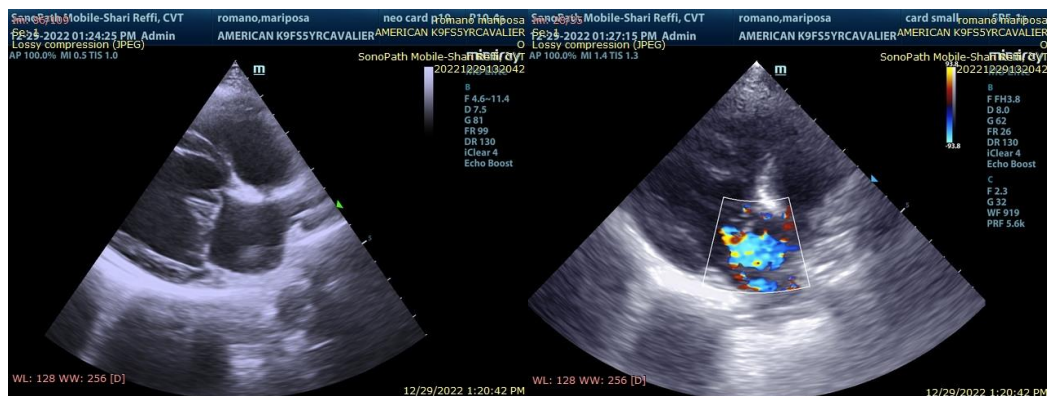
12.3 lb

HOSPITAL NAME

American AH

REFERRING VET

Dr. Stockmal





DATE

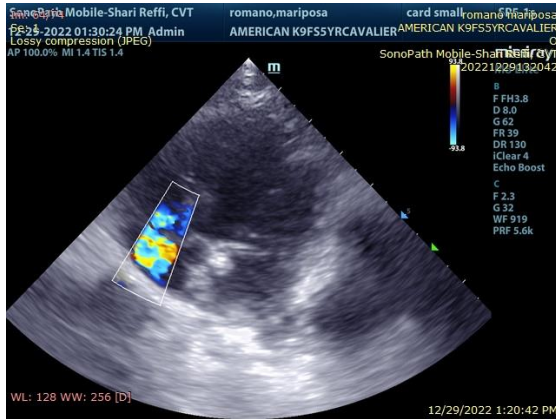
12/30/22

PERFORMED BY:

Shari Reffi, CVT

INTERPRETED BY

Keith Blass, DVM,
MS, DACVIM
(Cardiology)



The information and recommendations provided are based on the images presented by the referring veterinarian. No evaluation can be communicated regarding pathology that was not visible in the image/video clips provided.

PATIENT

Thank you for this referral. If the clinical or image interpretation does not parallel your findings or if I can be of any further assistance please contact me.

Mariposa Romano

Keith Blass, DVM, MS, DACVIM (Cardiology)
KeithBlass@gmail.com
631-804-5754

SPECIES

Canine

BREED

CKCS

SEX

FS

AGE

5 y

WEIGHT

12.3 lb

HOSPITAL NAME

American AH

REFERRING VET

Dr. Stockmal